

expected with the standard counterstain. The calcium phosphate salts in Figure 1 are black and dark grey, whereas in undecalcified tissue sections stained with hematoxylin-eosin, the calcium is usually an intense basophilic blue-purple. When the von Kossa staining method is used, silver replaces the calcium (or another substance) and shows up as black or very dark burnt umber, as in the authors' image.

#### Henry Schneiderman MD

Professor of Medicine (Geriatrics),  
Associate Professor of Pathology,  
University of Connecticut Health Center,  
Farmington, Conn.

Competing interests: None declared.

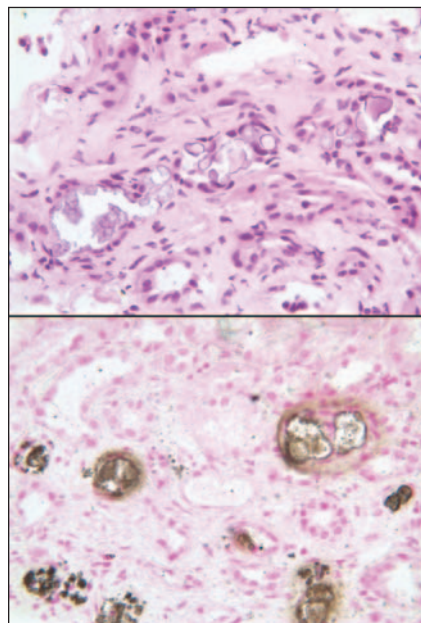
#### REFERENCE

- Schattner A, Kopolovic J, Melzer E, et al. A 71-year-old woman with abdominal pain and acute renal failure. *CMAJ* 2007;177:454-5.

DOI:10.1503/cmaj.1070130

#### [Two of the authors respond:]

We thank Henry Schneiderman for his comments on the stain we used to demonstrate the calcium deposits in



**Figure 1:** A kidney biopsy showing tubular atrophy and multiple calcium deposits (original magnification  $\times 400$ ) stained with hematoxylin-eosin stain (top) and von Kossa stain (bottom).

the tubular lumina of our patient's kidney.<sup>1</sup> Schneiderman is right, of course, and we appreciate his meticulous and observant reading of our paper.

We made a special effort to use the von Kossa staining method for this kidney biopsy. This staining method is used as a histochemical method for calcium, but it is really a method for phosphate and carbonate. The calcium in the tissue section is replaced by silver; in the presence of phosphate and carbonate the silver is reduced to form crystals of silver phosphate and silver carbonate, which appear black and have a unique appearance in histologic sections. Figure 1 shows the 2 staining methods we used for our patient's kidney biopsy, which produced clearly different results. Hematoxylin-eosin staining was mentioned in our article by mistake; we apologize for this error.

#### Ami Schattner MD

Department of Medicine

#### Juri Kopolovic MD

Department of Pathology, Hebrew  
University and Hadassah Medical School,  
Jerusalem, Israel

Competing interests: None declared.

#### REFERENCE

- Schattner A, Kopolovic J, Melzer E, et al. A 71-year-old woman with abdominal pain and acute renal failure. *CMAJ* 2007;177:454-5.

DOI:10.1503/cmaj.1070131

## Interprofessional collaboration

In a recent *CMAJ* news article, Wayne Kondro referred to a patient-centred collaborative care model adopted by delegates to the Canadian Medical Association's 140th General Council.<sup>1</sup> The model's focus on the physician as clinical leader does not capture the synergistic nature of collaborative practice.<sup>2</sup> Only through interprofessional communication and sharing of knowledge and skills can the provision of care be enhanced.<sup>3</sup>

In its position statement *Interprofessional Collaboration*, the Canadian Nurses Association stresses the importance of the health needs of individual clients and patients and of the popula-

tion as determinants of care provision.<sup>3</sup> It states, "The right service is provided at the right time, in the right place and by the right care provider."

Mutual trust and respect are essential elements of interprofessional communication. If these elements are truly present, then members of the health care team can together determine, on the basis of their shared understanding of each other's roles and expertise, who will lead the team in a given patient care context.

Collaborative practice requires negotiation and a noncompetitive, non-hierarchical approach to patient and client care.<sup>4</sup> Until health care workers agree on what collaborative practice entails at all levels of the health care system, true interprofessional collaborative practice will not be observed and the benefits it offers will not be reaped.

#### Marlene Smadu RN EdD

President, Canadian Nurses Association,  
Ottawa, Ont.

Competing interests: None declared.

#### REFERENCES

- Kondro W. Canada's doctors assail pharmacist prescribing. *CMAJ* 2007;177:558.
- Way DO, Jones L, Busing N. Implementation strategies: "Collaboration in primary care — family doctors and nurse practitioners delivering shared care" [discussion paper]. Toronto: Ontario College of Family Physicians; 2000.
- Canadian Nurses Association. Interprofessional collaboration [position statement]. Ottawa: The Association; 2006.
- D'Amour D. La collaboration professionnelle: un choix obligé. In: Goulet O, Dallaire C, editors. *Les soins infirmiers. Vers de nouvelles perspectives*. Boucherville (QC): Gaëtan Morin Éditeur; 2002. p. 339-63.

DOI:10.1503/cmaj.1070156

## Correction

A News brief in the November 20 issue about the election of Dr. William Fitzgerald as the 40th president of the Royal College of Physicians and Surgeons should have identified Dr. Fitzgerald as president-elect as of September 2007 and president as of September 2008.<sup>1</sup>

#### REFERENCE

- Kondro W. News @ a glance. *CMAJ* 2007; 177:1346.

DOI:10.1503/cmaj.071790