

Anterior uveitis and diffuse scleritis after pamidronate infusion

Jim S. Xie BHSc, Alexander J. Kaplan MD

■ Cite as: *CMAJ* 2023 December 18;195:E1722. doi: 10.1503/cmaj.230859

A 58-year-old, bisphosphonate-naive woman with a history of Hashimoto thyroiditis was admitted to hospital for hypercalcemia (2.81 [normal 2.20–2.60] mmol/L) due to primary hyperparathyroidism. She received 60 mg of intravenous pamidronate. Two days later, she developed right eye pain, photophobia and blurred vision, with progressive redness and periorbital swelling. She presented to an emergency eye clinic 6 days later and had a visual acuity of 20/30 in the left eye and only light perception in the right eye, with proptosis, an adduction deficit, corneal edema and a hypopyon (Figure 1A). The posterior segment view was obstructed but no vitritis was seen on B-scan ultrasonography. Computed tomography of the orbits revealed right-sided diffuse scleral thickening (Figure 1B). She was treated empirically with topical moxifloxacin, corticosteroids and cycloplegics. Infectious and inflammatory work-up was negative, apart from an elevated C-reactive protein (16.4 [normal < 3] mg/L).

We saw the patient a week later and diagnosed drug-induced anterior uveitis with scleritis from the pamidronate infusion. Her intraocular inflammation resolved after starting oral corticosteroids with a slow taper. At the 7-week follow-up visit, her visual acuity in the right eye had improved to 20/50. The patient eventually received a parathyroidectomy, which resolved her hypercalcemia.

The differential diagnosis of anterior uveitis with scleritis includes infectious, autoimmune, traumatic, neoplastic and drug-induced causes. For this patient, neoplasm was ruled out as she had no posterior segment involvement. Infectious and autoimmune disorders were considered and empirically treated pending investigations, which later returned as negative. Drug-induced uveitis or scleritis may be seen with use of parenteral or oral bisphosphonates, with incidence rates of 7–114 per 10 000 and 8–63 per 10 000 people per year, respectively.^{1,2} Onset of uveitis or scleritis tends to be faster after parenteral (1–7 d) than oral (days to months) bisphosphonates.² If patients develop red eye associated with pain, photophobia, blurred vision, or periorbital swelling within a week of new medication exposure, the medication

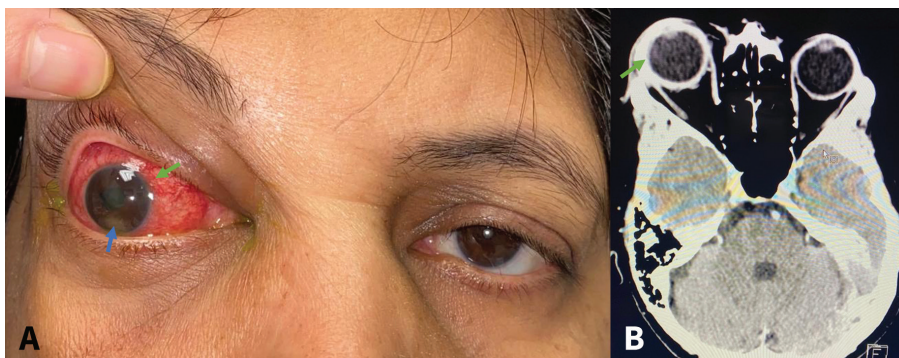


Figure 1: A) Pamidronate-induced anterior uveitis and diffuse scleritis in a 58-year-old woman. Proptosis, hypopyon (blue arrow) and scleral injection and edema (green arrow) began within 48 hours of pamidronate infusion. B) A computed tomography scan of the orbits showed right-sided proptosis and circumferential scleral thickening and hypervascularity with adjacent edema (green arrow), consistent with diffuse scleritis.

should be stopped immediately. Suspected drug-induced uveitis is managed empirically with topical corticosteroids and antibiotics with close follow-up by an ophthalmologist.³

References

1. French DD, Margo CE. Postmarketing surveillance rates of uveitis and scleritis with bisphosphonates among a national veteran cohort. *Retina* 2008;28:889-93.
2. Chartrand NA, Lau CK, Parsons MT, et al. Ocular side effects of bisphosphonates: a review of literature. *J Ocul Pharmacol Ther* 2023;39:3-16.
3. Abdalla Elsayed MEA, Kozak I. Pharmacologically induced uveitis. *Surv Ophthalmol* 2021;66:781-801.

Competing interests: None declared.

This article has been peer reviewed.

The authors have obtained patient consent.

Affiliations: Michael G. DeGroot School of Medicine (Xie), McMaster University, Hamilton, Ont.; Department of Ophthalmology and Vision Sciences (Kaplan) and Toronto Western Hospital (Kaplan), University of Toronto, Toronto, Ont.

Content licence: This is an Open Access article distributed in accordance with the terms of the Creative Commons Attribution (CC BY-NC-ND 4.0) licence, which permits use, distribution and reproduction in any medium, provided that the original publication is properly cited, the use is non-commercial (i.e., research or educational use), and no modifications or adaptations are made. See: <https://creativecommons.org/licenses/by-nc-nd/4.0/>

Correspondence to: Alexander Kaplan, alexander.kaplan@uhn.ca