

# A false-positive troponin assay leading to the misdiagnosis of myopericarditis

Marianne Laguë MD, Pierre Yves Turgeon MD, Sébastien Thériault MD, Christian Steinberg MD

■ Cite as: *CMAJ* 2022 March 28;194:E456-9. doi: 10.1503/cmaj.211842

**A** 16-year-old girl who was an avid triathlete was transferred to our hospital with a working diagnosis of persistent myopericarditis. Her medical history was unremarkable and she had not received a vaccine against SARS-CoV-2. She had initially presented to an emergency department with atypical chest pain. Her vital signs and cardiac examination were normal. Serial electrocardiograms (ECGs) showed normal sinus rhythm (Figure 1A). A high-sensitivity assay (Dimension Vista 1500, Siemens Healthineers) showed elevated cardiac troponin I (cTnI), with an initial result of 872 ng/L (99th percentile upper limit of normal [ULN] in women 54 ng/L). A transthoracic echocardiogram and a ventilation–perfusion lung scan were normal. The patient was discharged with a presumptive diagnosis of myopericarditis and was prescribed naproxen and colchicine. Her cTnI level remained elevated at an outpatient visit 7 days later (Figure 1B). Cardiac magnetic resonance imaging showed no evidence of myocardial inflammation. Because of the possibility of persistent myopericarditis, a short course of prednisone was started.

One month later, the patient was readmitted to hospital following a repeat episode of atypical chest pain with very elevated cTnI (3165 ng/L, Dimension Vista 1500). Her physical symptoms were nonspecific and included exertional dyspnea and fatigue. The referring cardiologist resumed anti-inflammatory therapy (Figure 1B) for a short period. Considering her unusual clinical course and the unexpected increase in troponin levels (Figure 1B), the patient was transferred to our centre for further investigations.

At our hospital, laboratory testing showed no evidence of systemic inflammation (normal levels of white blood cells, erythrocyte sedimentation rate and C-reactive protein). Renal and liver function were normal. Results from serial ECGs, 7-day telemetry monitoring, exercise treadmill testing and signal-averaged ECGs were unremarkable. Additional cardiac imaging — including transthoracic echocardiography with strain analysis (Figure 1C), repeat cardiac resonance imaging, coronary magnetic resonance angiography (to exclude anomalous coronary arteries) and fluorodeoxyglucose positron emission tomography (to exclude cardiac inflammation, such as sarcoidosis) — was normal. The patient had no evidence of any inflammatory, autoimmune or infectious disease after testing for rheumatoid factor, antinuclear

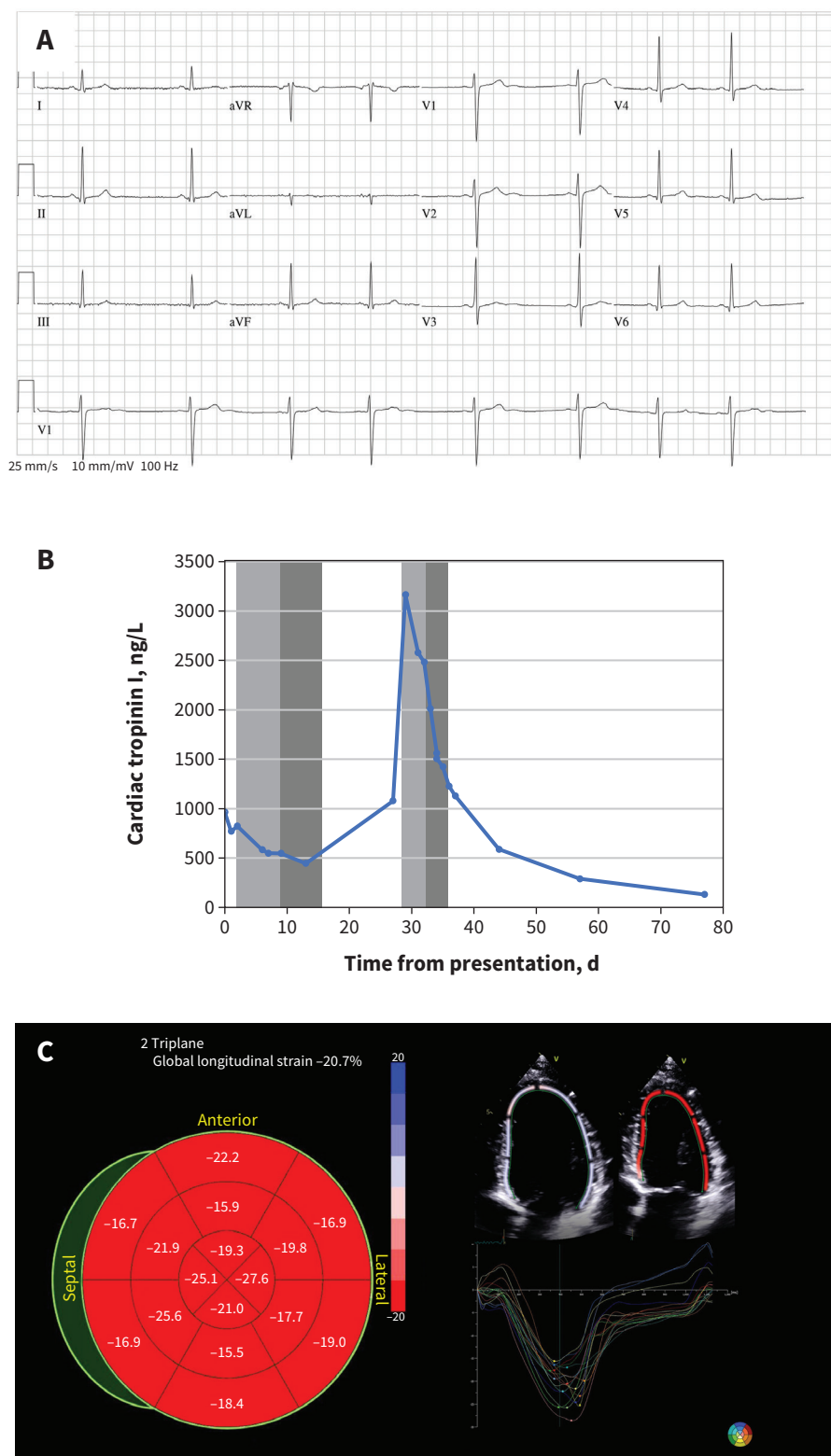
## Key points

- High-sensitivity troponin immunoassays are subject to false-positive error from either *in vivo* or *in vitro* interference, attributed to heterophilic antibodies, autoantibodies or macrotroponin.
- Macrotrponin, a complex of immunoglobulin and cardiac troponin (most often cardiac troponin I), is the most common cause of falsely elevated troponin levels.
- Clinicians should consider the possibility of a falsely elevated troponin when they observe discordance between the troponin level and the patient's clinical presentation.
- Early recognition of a false-positive troponin elevation could spare patients invasive and expensive procedures and mitigate anxiety.

antibodies, SARS-CoV-2, Epstein–Barr virus and HIV. Genetic testing for hereditary cardiomyopathies was negative.

These negative findings on an extensive workup for myocardial injury made us suspicious that the results of the cTnI assays were false positives, a suspicion supported by normal levels of creatine kinase-MB at less than 1.0 (ULN 8.0) µg/L and of cardiac troponin T (cTnT) at 12 (ULN 14) ng/L from a high-sensitivity assay (Cobas, Roche Diagnostics). We therefore undertook additional biochemical testing. Analysis of cTnI with another method (Vitros 5600, Ortho Clinical Diagnostics) was close to normal at 11 (ULN 9) ng/L. To assess the possibility of circulating macrotroponin, we conducted a precipitation test with polyethylene glycol (PEG), which showed an initial recovery of 31%, followed by 21% after dilution (the recovery threshold for a positive test has been suggested as < 40%).<sup>1</sup> Therefore, we concluded that the presence of circulating macrotroponin likely caused false-positive TnI results on the Siemens' Dimension Vista 1500 assays.

Reviewing the patient's entire clinical course, we considered that the most likely diagnosis was musculoskeletal pain, and anxiety after her first episode of chest pain that was likely exacerbated by the false diagnosis of myopericarditis. We reassured the patient and discharged her without medication. She had no further episodes despite progressively resuming sport training. One year later, the result of a cTnI test was still slightly positive (130 ng/L, Dimension Vista 1500).

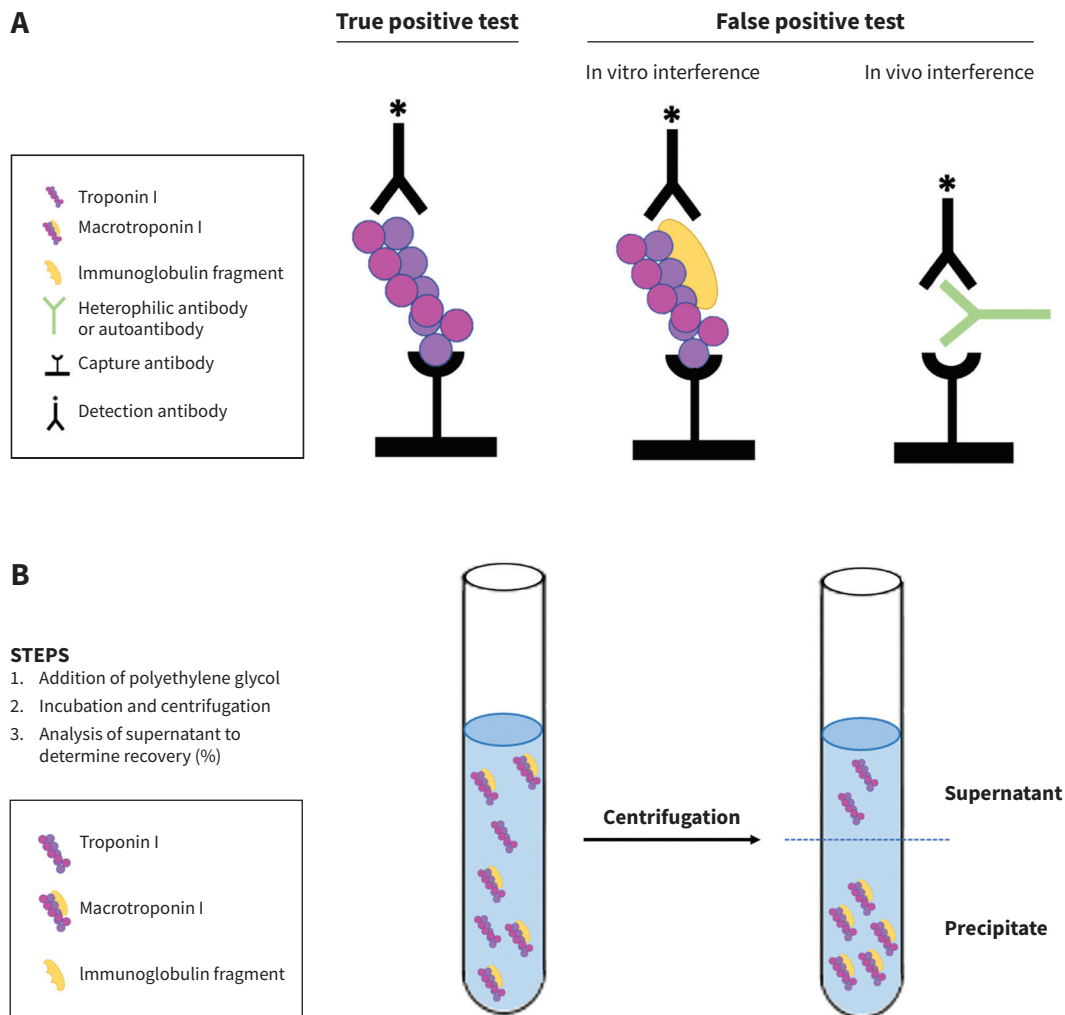


**Figure 1:** Cardiac investigations of a 16-year-old girl with a misdiagnosis of myopericarditis. (A) Normal electrocardiogram from the patient's initial presentation to the emergency department. (B) Cardiac troponin I levels and anti-inflammatory treatments from initial presentation to 80 days after presentation. Light grey and dark grey bars represent duration of anti-inflammatory treatment with naproxen and prednisone, respectively. (C) Transthoracic echocardiogram from 30 days after the patient's initial presentation, at time of the maximum level of cardiac troponin I, showing normal global longitudinal strain.

## Discussion

Clinicians should consider the possibility of a falsely elevated troponin when they observe discordance between the troponin level and the patient's clinical presentation. High-sensitivity troponin immunoassays are subject to false-positive error from either *in vivo* or *in vitro* assay interference (Figure 2A), which can be caused by heterophilic antibodies, autoantibodies or macrotroponin.<sup>2</sup> A previous study found discordance rates of about 1.5% when comparing results from 2 different cTnI assays, most of which were attributed to the presence of a macrotroponin.<sup>3</sup> These elevated cTnI levels from high-sensitivity assays can be clinically misleading, but most false-positive results are small elevations.

The authors of a 2013 review of heterophilic antibody interference in immunometric assays suggested that heterophilic antibodies with affinity to animal antibodies are present in as many as 40% of the population, most often without a known exposure to animal antigens.<sup>4</sup> They are an endogenous cause of *in vitro* analytical interference. In rare cases, the presence of heterophilic antibodies may lead to false-positive results as they can interact with the animal immunoglobulins in certain reagents, despite optimization of most assays to avoid this interference. A serial dilution of the sample to look for nonlinearity in the cTnI concentration or another analysis of the sample in heterophilic blocking tubes to neutralize the antibodies can help make the diagnosis. We did not perform serial dilution in our patient, and heterophilic blocking tubes are not readily available in our centre.



**Figure 2:** (A) Mechanisms for *in vivo* and *in vitro* analytic interference with troponin assays. The presence of a macrotroponin, a high-molecular-weight complex of immunoglobulin and troponin, can lead to false-positive results owing to its slower clearance from circulation. The presence of heterophilic antibodies or autoantibodies can lead to false-positive results by bridging the assay's capture and detection antibodies, generating a false signal. (B) Polyethylene glycol (PEG) precipitation test to assess possibility of circulating macrotroponin. The addition of PEG leads to the precipitation of high-molecular-weight molecules, including macrotroponin. After incubation with PEG and centrifugation, the supernatant, now cleared from macrotroponin, is measured and the recovery rate can be calculated (supernatant troponin concentration, corrected for the volume of PEG, divided by the initial troponin result). A low recovery rate suggests the presence of macrotroponin.

Circulating autoantibodies against cTnI or cTnT can cause analytical interference and are sometimes associated with autoimmune disorders such as rheumatoid arthritis.<sup>5</sup> The prevalence of cTnI autoantibodies has been reported to be as high as 12.7% in normal blood donors.<sup>5</sup>

Macro-troponin, a complex of immunoglobulin and cardiac troponin (most often cTnI), is the most common cause of discrepancies between different troponin assays.<sup>1,6</sup> A recent study showed a potentially higher incidence of false-positive results from macro-troponin with Siemens cTnI assays, including the one used in our case.<sup>1</sup> These high-molecular-weight immune complexes result from the binding of protein fragments or enzymes with circulating immunoglobulins, with or without cardiac muscle injury. This phenomenon has also been observed with several other biomarkers, notably creatine kinase, aspartate aminotransferase, amylase and prolactin. These complexes tend to persist in the blood owing to their reduced clearance and increased half-life, resulting in falsely elevated levels of the biomarker. The troponin level measured by immunoassays when macro-troponins are present is unpredictable, but it often produces an elevation over the 99th percentile.<sup>6</sup> The presence of these physiologically inactive immune complexes has been proposed to result from prior sensitization with infectious antigens, or with immunization to cTnI or cTnT after myocardial injury or muscle damage.<sup>5</sup>

Many biochemical tests can be used to confirm the presence of macro-troponin; PEG precipitation tests are increasingly used for this purpose (Figure 2B).<sup>1</sup> The patient's serum is mixed with PEG and, after an incubation period that allows for heavy complexes to precipitate, the supernatant is then reanalyzed. Low recovery of cTnI indicates the presence of macro-troponin. The level of recovery after PEG precipitation that determines the presence of a macro-troponin is not well established and likely depends on the protocol and the assay that is used, as well as the troponin level. A study of 6 different assays proposed a threshold of 40% recovery and showed good concordance between PEG precipitation and incubation with protein A at this threshold.<sup>1</sup> Although other studies have used lower thresholds, the recovery observed in our case was lower than what has been reported in control samples.<sup>3,6</sup> Precipitation with an immunoglobulin-binding protein, like protein A, protein G or another antihuman immunoglobulin G (IgG), is another method to initiate immunoglobulin depletion, which has been shown to have a good concordance with PEG precipitation but is not readily available in our centre.<sup>1,6</sup> Removing the IgG fragment of the macrocomplex and subsequently measuring cTnI and IgG levels can also indicate the presence of a macro-troponin.

In our patient, we identified macro-troponin I using PEG precipitation. Notably, it was not detected using a different cTnI assay, which could be attributed to the 2 assays recognizing different epitopes. Although less common, we cannot exclude the presence of a heterophilic or other antibody contributing to assay interference in our patient. Interestingly, the patient's serial cTnI levels decreased on follow-up assays; it is possible that the anti-inflammatory treatments she was prescribed caused a decrease in antibody production.

Myopericarditis has the same pathophysiology as myocarditis. For myocarditis, the inflammation is located exclusively in the myocardium, whereas the pericardium is also affected in myopericarditis. The inflammation of the pericardium can cause

the typical pleuritic pain of pericarditis, which is worsened by supine position. Other than the spurious troponin elevation, this patient had no specific symptoms or signs of myopericarditis or pericarditis after extensive work-up.

Our case stresses the importance of carefully interpreting laboratory results in the clinical context of each patient, with special attention given to cases with discordance. When discordance is observed, a different laboratory method for quantification of cardiac troponin levels can be used to identify false-positive results. The early recognition of false-positive elevations in troponin could spare patients many invasive and expensive procedures and mitigate anxiety.

## References

1. Lam L, Aspin L, Heron RC, et al. Discrepancy between cardiac troponin assays due to endogenous antibodies. *Clin Chem* 2020;66:445-54.
2. Mair J, Lindahl B, Muller C, et al. What to do when you question cardiac troponin values. *Eur Heart J Acute Cardiovasc Care* 2018;7:577-86.
3. Warner JV, Marshall GA. High incidence of macro-troponin I with a high-sensitivity troponin I assay. *Clin Chem Lab Med* 2016;54:1821-9.
4. Bolstad N, Warren DJ, Nustad K. Heterophilic antibody interference in immuno-metric assays. *Best Pract Res Clin Endocrinol Metab* 2013;27:647-61.
5. Adamczyk M, Brashear RJ, Mattingly PG. Circulating cardiac troponin-I auto-antibodies in human plasma and serum. *Ann N Y Acad Sci* 2009;1173:67-74.
6. Kavsak PA, Roy C, Malinowski P, et al. Macrocomplexes and discordant high-sensitivity cardiac troponin concentrations. *Ann Clin Biochem* 2018;55:500-4.

**Competing interests:** None declared.

This article has been peer reviewed.

The authors have obtained patient consent.

**Affiliations:** Faculty of Medicine (Laguë), Université Laval; Departments of Cardiology (Turgeon, Steinberg), and of Molecular Biology, Medical Biochemistry and Pathology (Thériault), Institut Universitaire de Cardiologie et Pneumologie de Québec, Québec, Que.

**Contributors:** All of the authors contributed to the conception and design of the work. Marianne Laguë and Pierre Yves Turgeon drafted the manuscript. All authors revised it critically for important intellectual content, gave final approval of the version to be published and agreed to be accountable for all aspects of the work.

**Content licence:** This is an Open Access article distributed in accordance with the terms of the Creative Commons Attribution (CC BY-NC-ND 4.0) licence, which permits use, distribution and reproduction in any medium, provided that the original publication is properly cited, the use is noncommercial (i.e., research or educational use), and no modifications or adaptations are made. See: <https://creativecommons.org/licenses/by-nc-nd/4.0/>

**Correspondence to:** Pierre Yves Turgeon, pierre-yves.turgeon@cricuq.ulaval.ca

The section Cases presents brief case reports that convey clear, practical lessons. Preference is given to common presentations of important rare conditions, and important unusual presentations of common problems. Articles start with a case presentation (500 words maximum), and a discussion of the underlying condition follows (1000 words maximum). Visual elements (e.g., tables of the differential diagnosis, clinical features or diagnostic approach) are encouraged. Consent from patients for publication of their story is a necessity. See information for authors at [www.cmaj.ca](http://www.cmaj.ca).