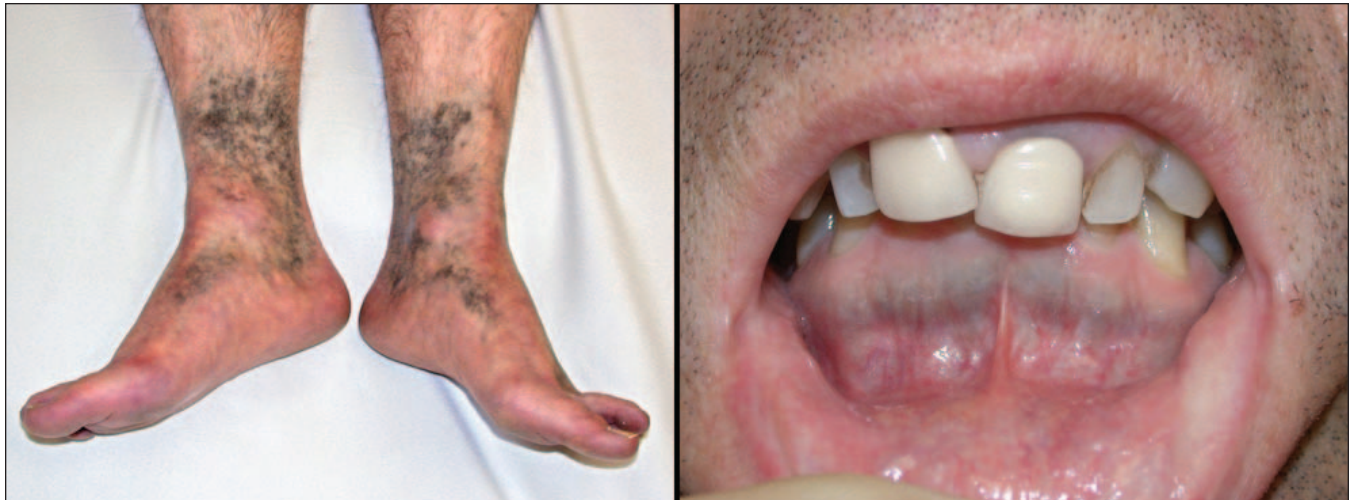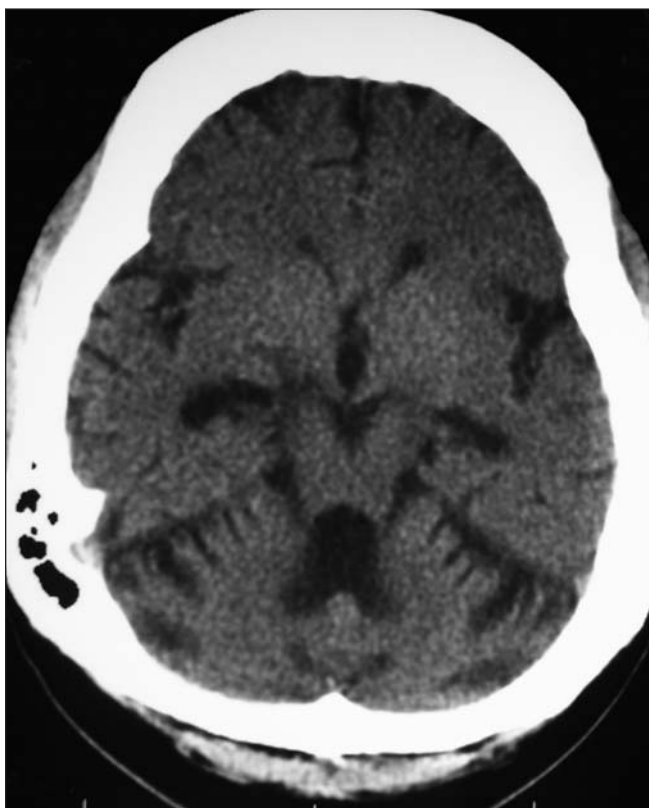


CLINICAL VISTAS BRIEFS

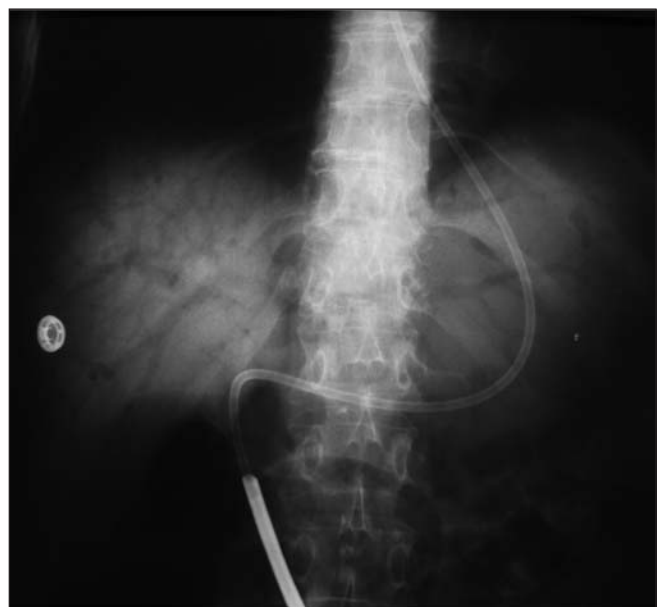What's your call?



A 45-year-old man with scleroderma presented with a 3-year history of blue skin discoloration on his legs, feet and gingival margin.



Axial plain CT scan of a 31-year-old woman with long-standing epilepsy who injured her head during a seizure.



Plain film radiograph of a 52-year-old woman with known Crohn's disease who presented with acute abdominal pain and hypotension.

See pages 322 and 323 for diagnoses.

CLINICAL VISTAS BRIEFS

Hyperpigmentation associated with minocycline therapy

The patient had a long history of Raynaud's phenomenon, acid reflux disease and skin tightening over his fingers, hands, forearms and face. Five years earlier, he had received a diagnosis of diffuse scleroderma.

An early open-label trial of minocycline involving a small number of patients with early diffuse scleroderma had suggested the drug's efficacy in reducing skin tightness. Based on this report, the patient had been prescribed minocycline therapy by his rheumatologist 5 years before presentation. The patient reported noticing skin discoloration on his legs and feet over the last 3 years. There was no pruritus or pain, sclerodermatous thickening of skin on the legs or any sensory abnormalities. He also reported noticing pigmentation on the lower gingival margin.

Tetracycline and its analogues have traditionally been used for the treatment of acne; however, their role in inflammation and their therapeutic effect in diseases such as rosacea, bullous disorders, neutrophilic dermatoses, pyoderma gangrenosum, sarcoidosis, rheumatoid arthritis and scleroderma have been investigated. In contrast to earlier findings, a more recent larger study suggested that minocycline is not an effective therapy for systemic sclerosis.¹

Long-term use of minocycline has been associated with non-dose-dependent blue-grey circumscribed pigmentation of clinically normal skin of the lower legs and mucosal pigmentation. Histologically, intracellular pigment is seen in the dermis and the subcutaneous tissue, which stains positively for melanin and iron.

In one study, hyperpigmentation occurred in 41% of patients with rheumatoid arthritis who had been taking minocycline for more than 3 months (median onset 12 months).² When not extensive, hyperpigmenta-

tion may at least partly regress after minocycline therapy is discontinued. Alexandrite laser therapy has been effective in treating minocycline-induced hyperpigmentation without scarring or hypopigmentation.

Soumya Chatterjee

Department of Rheumatic and Immunologic Diseases
Cleveland Clinic Foundation
Cleveland, Ohio

Competing interests: None declared.

REFERENCES

1. Mayes MD, O'Donnell D, Rothfield NF, et al. Minocycline is not effective in systemic sclerosis: results of an open-label multicenter trial. *Arthritis Rheum* 2004;50:553-7.
2. Roberts G, Capell HA. The frequency and distribution of minocycline induced hyperpigmentation in a rheumatoid arthritis population. *J Rheumatol* 2006;33:1254-7.

DOI:10.1503/cmaj.060866

Cerebral atrophy and skull thickening due to chronic phenytoin therapy

The woman had refractory epilepsy and mental insufficiency since 15 years of age following an episode of encephalitis. Her epilepsy showed a fair response to adjunctive vagus nerve stimulation (placement of a bipolar electrode delivering intermittent electrical pulses to the left vagus nerve) in addition to chronic antiepileptic drug therapy (including phenytoin, sodium valproate, pregabalin and clobazam). The patient had been treated with phenytoin since the age of 18.

At age 31, the patient underwent a CT scan after experiencing a head injury during a seizure (Fig. 1). The result of the CT scan is remarkable because it demonstrates 2 distinct effects of chronic anticonvulsant therapy: cerebellar atrophy and generalized thick-

ening of the skull vault. In this patient, cerebellar atrophy appears to have developed after the use of anticonvulsants rather than encephalitis. The chronological sequence makes post-encephalitis changes less likely, however this possibility cannot be completely excluded.

The adverse effects of phenytoin on skull thickening have long been recognized.¹ Phenytoin has recently been shown to stimulate osteoblast proliferation and differentiation via upregulation of transforming growth factor- β 1 and bone morphogenetic proteins. The exact incidence of calvarial thickening is unknown, but has been reported to be 34% among patients with seizure disorder in institutions.² The clinical implications of skull thickening appear to be largely cosmetic: the degree of skull thickening correlates with frontal bossing (acromegaloid features with normal hand and foot size) and the degree of facial coarsening.

Other causes of bilateral hyperostosis of the skull vault, such as marrow hyperplasia secondary to thalassemia major, hyperparathyroidism, acromeg-

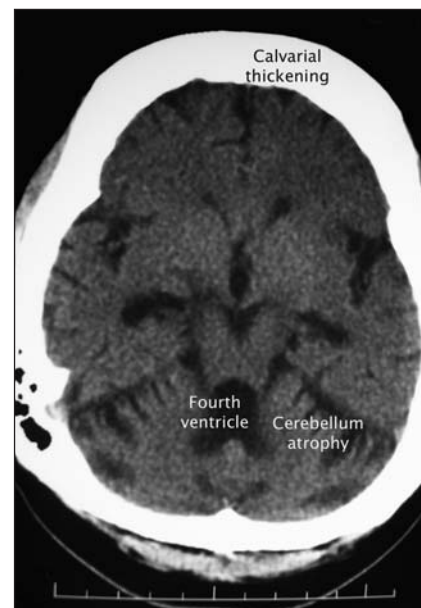


Fig. 1: Axial plain CT scan after prolonged anticonvulsant therapy showing cerebellar atrophy with secondary dilation of the fourth ventricle and marked (symmetrical) hyperostosis of the skull.

aly and osteopetrosis, were not evident in this patient.

Kai Ming Chow

Cheuk Chun Szeto

Department of Medicine

and Therapeutics

Prince of Wales Hospital

Chinese University of Hong Kong

Hong Kong

Competing interests: None declared.

REFERENCES

1. Kattan KR. Calvarial thickening after Dilantin medication. *Am J Roentgenol Radium Ther Nucl Med* 1970;110:102-5.
2. Lefebvre EB, Haining RG, Labbe RF. Coarse facies, calvarial thickening and hyperphosphatasia associated with long-term anticonvulsant therapy. *N Engl J Med* 1972;286:1301-2.

DOI:10.1503/cmaj.061171

Gas in the portomesenteric vessels from nonocclusive ischemic bowel disease

A woman with known Crohn's disease and a previous partial resection of her small intestine presented with a poor appetite, weight loss, diarrhea and malnutrition. She was an ex-smoker and was taking antihypertensive therapy. Results of an upper gastrointestinal series showed stenotic areas in the ileum. The patient was admitted to hospital with a presumed exacerbation of inflammatory bowel disease. However, acute abdominal pain and distension developed despite treatment, and she became hypotensive and nonresponsive. Resuscitation efforts were initiated, and a nasogastric tube was inserted which drained bloody fluid. A plain abdominal radiograph (Fig. 1) showed air in the portomesenteric vascular system. Gastroscopy was per-

formed and showed extensive mucosal ulcerations. An emergency laparotomy revealed zones of necrosis throughout the small intestine and bowel; however, no curative treatment could be done, and the woman died shortly after withdrawal of life support. Autopsy revealed extensive nontransmural gastric ulcers, necrotic areas in the small and large intestines, and nonocclusive atheromatous plaques in the aorta and at the origin of the inferior mesenteric artery. The final diagnosis was ischemic enterocolitis due to nonocclusive arterial stenosis and diffuse atheromatosis.

The presence of gas in the portomesenteric circulation is an uncommon sign of ischemic enterocolitis, but its significance should not be overlooked. Gas is thought to enter the portomesenteric circulation following an injury to the gastrointestinal tract. This is most often due to mesenteric ischemia but may also occur following ulceration of the mucosa or abdominal sepsis. Portomesenteric venous gas can be differentiated from biliary gas by its location: portomesenteric gas is peripheral and extends near or out of the hepatic capsula, whereas biliary gas is more central because of the centripetal flow of bile.¹

Nonocclusive, or nongangrenous, ischemic colitis occurs when blood flow through small watershed vessels is altered by a variety of conditions, including severely low blood flow due to nonobstructive stenosis, shock, small-vessel disease, vasospasm, hypercoagulable states and use of certain medication, such as cocaine, ergotamine, amphetamine, pseudoephedrine, vasopressin, sumatriptan, oral contraceptive (venous thrombosis) and digitalis. The cause of ischemic enterocolitis in this patient was partial obstruction of the inferior mesenteric artery and diffuse small-artery disease throughout the distal mesenteric microcirculation. Nonocclusive ischemic colitis can present similarly to Crohn's disease with a subacute pattern of mild repeated injury

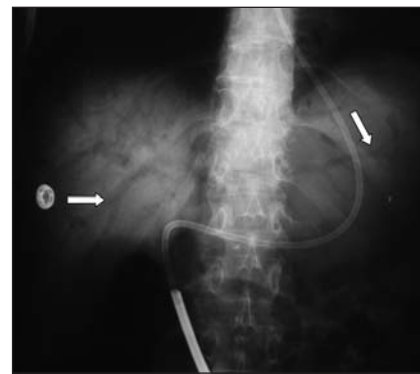


Fig. 1: Plain film radiograph showing air in the portomesenteric circulation (arrows).

(chronic enteritis). However, it is more commonly heralded by the sudden onset of severe crampy abdominal pain and diarrhea mixed with bright red blood and occasionally melena. The abdomen is often distended, and bowel sounds are usually present. Peritoneal signs are absent unless necrosis becomes transmural. The diagnosis can be confirmed by imaging (urgent doppler ultrasonography of mesenteric vessels, CT scanning, conventional or magnetic resonance angiography). In the absence of spontaneous resolution with supportive measures, treatment of strictures and ulceration is often surgical and has mixed results.

Isabelle Nault

Department of Cardiology

Hôpital Laval

Claude Lauzon

Department of Internal Medicine

Centre Hospitalier de la Région

de l'Amiante

Québec, Que.

Competing interests: None declared.

REFERENCE

1. Sebastia C, Quiroga S, Espin E, et al. Portomesenteric vein gas: pathologic mechanisms, CT findings and prognosis. *Radiographics* 2000;20:1213-24.

DOI:10.1503/cmaj.060807