

Severe vitamin B₁₂ deficiency causing pseudo-thrombotic microangiopathy

Aidan McKee MD, Brittany Salter MD PhD, Siraj Mithoowani MD MHPE

■ Cite as: *CMAJ* 2023 October 3;195:E1300-4. doi: 10.1503/cmaj.230959

A 76-year-old man presented to the emergency department of a community hospital with a 6-month history of generalized weakness, fatigue, decreased appetite, 25-lb weight loss and exertional dyspnea. He had no infectious symptoms or bleeding. He did not have any personal or family history of hematologic disorders, and his only notable past medical history was vitiligo. On examination in the emergency department, he had scleral icterus and skin hypopigmentation consistent with vitiligo, and his vital signs were normal. He had no palpable hepatosplenomegaly or lymphadenopathy, and his neurologic examination was unremarkable.

Initial bloodwork showed pancytopenia with a hemoglobin level of 45 (normal 135–175) g/L, mean corpuscular volume of 111 (normal 80–100) fL, leukocyte count of 2.9 (normal 4.0–11.0) × 10⁹/L and platelet count of 68 (normal 150–400) × 10⁹/L. His last complete blood count from 3 years ago was normal. Additional investigations showed unconjugated bilirubinemia, markedly elevated lactate dehydrogenase (LDH), schistocytes on peripheral blood film and an inappropriately normal level of reticulocytes, given the severity of his anemia, as well as findings suggestive of coagulation abnormalities. (Table 1). Renal function was normal. High-sensitivity troponin levels and electrocardiography were unremarkable.

The patient was admitted to hospital and was seen the next day by an internal medicine physician. He was transfused with 4 units of packed red blood cells for his anemia. Given the combination of hemolysis, thrombocytopenia and presence of schistocytes, the physicians were concerned that he had a thrombotic microangiopathy (TMA), namely thrombotic thrombocytopenic purpura (TTP). The patient's PLASMIC score (a diagnostic tool for TTP) was 5, representing intermediate risk of severe ADAMTS13 enzyme deficiency.¹ He was started on 60 mg oral prednisone daily (1 mg/kg) and a continuous plasma infusion at 100 mL/hour, and was transferred to a tertiary care hospital for consultation with a hematologist and urgent plasma exchange.

Bloodwork on arrival to the tertiary care hospital showed worsening thrombocytopenia (26 × 10⁹/L), absent haptoglobin and a markedly elevated D-dimer level. The patient's International Society for Thrombosis and Hemostasis disseminated intravascular coagulation (DIC) score was 7, indicative of overt

Key points

- The clinical spectrum of vitamin B₁₂ deficiency can range from asymptomatic to life-threatening; some patients present with pancytopenia and intramedullary hemolysis causing pseudo-thrombotic microangiopathy (pseudo-TMA).
- Vitamin B₁₂ deficiency-associated pseudo-TMA is commonly misdiagnosed as thrombotic thrombocytopenic purpura (TTP); compared with TTP, it is associated with a higher lactate dehydrogenase level, more severe anemia, lower reticulocyte count, more severely elevated mean corpuscular volume and neutropenia.
- Treatment of pancytopenia from vitamin B₁₂ deficiency consists of intramuscular injections of vitamin B₁₂.
- A vitamin B₁₂ level should be routinely ordered in patients with suspected TMA.

DIC. We repeated the blood film after transfusion, which was negative for schistocytes but showed hypersegmented neutrophils, thrombocytopenia and red cell anisopoikilocytosis (Figure 1). Additional investigations excluded antiphospholipid syndrome, autoimmune hemolytic anemia and paroxysmal nocturnal hemoglobinuria as a cause of the patient's condition (Table 1). We obtained a serum vitamin B₁₂ level on day 2 of hospital admission, which was below the laboratory's limit of detection (< 117 [normal 138–652] pmol/L).

Based on the undetectable serum vitamin B₁₂ level, we diagnosed severe vitamin B₁₂ deficiency resulting in pancytopenia, intramedullary hemolysis and DIC. We stopped the plasma infusion and corticosteroids on the third day of admission, and did not start plasma exchange. Several days later, the patient's ADAMTS13 level was reported to have returned to normal at 56%, with no evidence of anti-ADAMTS13 antibodies, ruling out a diagnosis of TTP.

We administered intramuscular vitamin B₁₂ (1000 µg daily) beginning on the third day of admission, followed by oral vitamin B₁₂ at discharge. The patient's blood work abnormalities improved over his 7-day hospital stay (Table 2). At a follow-up visit 1 month after discharge, his symptoms had resolved, all hematologic values were improving and his vitamin B₁₂ level were normal. The patient's anti-parietal cell and anti-intrinsic

Table 1: Laboratory results included in the initial work-up and evaluation of a 76-year-old man with pseudo-thrombotic microangiopathy caused by severe vitamin B₁₂ deficiency

Investigation	Value	Reference range
Hemoglobin, g/L	45	135–175
MCV, fL	111	80–100
Platelets, × 10 ⁹ /L	68	150–400
Leukocytes, × 10 ⁹ /L	2.9	4–11
Neutrophils, × 10 ⁹ /L	1.8	2–6.3
Peripheral blood film	Few schistocytes, moderate dacrocytes	
INR	1.4	0.9–1.2
aPTT, s	30	27–42
Fibrinogen, g/L	1.5	1.9–4.7
Creatinine, µmol/L	92	64–111
Glomerular filtration rate predicted, mL/min	74	> 60
Total bilirubin, µmol/L	72.8	3.4–20.5
Unconjugated bilirubin, µmol/L	58	0–12
Conjugated bilirubin, µmol/L	14.8	1.6–8.6
Direct antiglobulin test	Negative	Negative
Lactate dehydrogenase, U/L	> 4500	110–230
Reticulocyte count, × 10 ⁹ /L	80	10–100
Haptoglobin, g/L	Absent	Present
High-sensitivity troponin, ng/L	10	< 34
Vitamin B ₁₂ , pmol/L*	< 117	138–652
Antiphospholipid antibody screen*	Negative	
D-dimer, ng/mL*	40 052	< 500
ANA screen*	Negative	
Rheumatoid factor, IU/mL*	15	< 10
ADAMTS13*, %	56	< 10 indicates severely decreased ADAMTS13 activity
Anti-ADAMTS13 antibodies*	Negative	Negative
Anti-parietal cell antibodies*	Negative	< 1:80
Anti-intrinsic factor antibodies*	Negative	Negative
Flow cytometry for paroxysmal nocturnal hemoglobinuria*	Negative	Negative

Note: aPTT = activated partial thromboplastin time, ADAMTS13 = a disintegrin and metalloproteinase with thrombospondin motifs 13, ANA = anti-nuclear antibody, INR = international normalized ratio, MCV = mean corpuscular volume.
*Laboratory tests ordered immediately upon transfer to tertiary care hospital (day 2 of hospital admission).

factor antibodies were negative, which decreased, but did not exclude, the likelihood of pernicious anemia as the cause of his vitamin B₁₂ deficiency.

Discussion

This case illustrates that the clinical spectrum of vitamin B₁₂ deficiency can include life-threatening illness, with hematologic derangements including pancytopenia, pseudo-TMA and overt DIC. Our patient's severe thrombocytopenia, positive hemolytic markers, schistocytes on peripheral blood film and markedly ele-

vated LDH level (> 1000 U/mL) all supported a possible diagnosis of TMA, with a differential diagnosis including TTP, hemolytic syndrome, atypical hemolytic syndrome or a TMA secondary to drugs, infection or malignant disease. Our differential diagnosis for his elevated LDH included other causes of hemolysis, infection, malignant disease, intracranial hemorrhage, myopathy and multiorgan failure (Box 1). Given his severe vitamin B₁₂ deficiency and normalization of hematologic derangements following vitamin B₁₂ treatment, we diagnosed severe vitamin B₁₂ deficiency. His presentation underscores the importance of ordering a vitamin B₁₂ level for unexplained cases of pancytopenia or suspected TMA.

Vitamin B₁₂ is essential for DNA synthesis, production of all hematologic cell lines and myelin synthesis.^{2,3} The prevalence of vitamin B₁₂ deficiency is estimated to be as high as 6%–20% in the United States.³ Vitamin B₁₂ deficiency is most commonly asymptomatic or mildly symptomatic and is frequently diagnosed in the outpatient setting. Typical symptoms include subacute or chronic onset of fatigue, palpitations, jaundice and neurologic abnormalities, including peripheral neuropathy, loss of proprioception and vibration sense or ataxia. Vitamin B₁₂ is present in foods of animal origin such as red meat, poultry, eggs and dairy products. Common causes of vitamin B₁₂ deficiency include malabsorption secondary to pernicious anemia, gastric or intestinal resection or inflammatory bowel

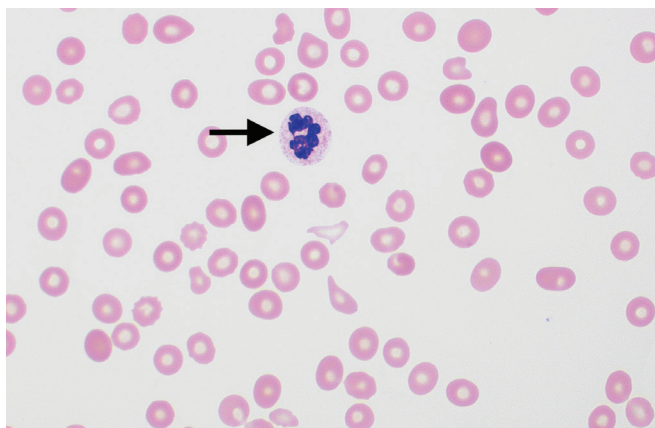


Figure 1: Peripheral blood film of a patient presenting with pseudo-thrombotic microangiopathy showing a hypersegmented neutrophil (arrow), thrombocytopenia and red cell anisopoikilocytosis (i.e., variation in red cell shape and size), indicating severe vitamin B₁₂ deficiency (Wright-Giemsa stain, ×100 magnification). Image courtesy of Drs. Shreyash Dalmia and Anath Lionel, Department of Medicine, McMaster University, Hamilton, Ont.

disease, iatrogenic causes such as long-term use of metformin or proton pump inhibitors, or dietary insufficiency secondary to veganism or alcohol use disorder.^{3,4} The cause of vitamin B₁₂

Box 1: Differential diagnosis for elevated lactate dehydrogenase (> 1000 U/mL)

- Hemolysis
 - Thrombotic microangiopathies such as thrombotic thrombocytopenic purpura, hemolytic uremic syndrome, atypical hemolytic uremic syndrome, disseminated intravascular coagulation, malignant hypertension, scleroderma renal crisis, catastrophic antiphospholipid syndrome
 - Other causes of intravascular hemolysis such as autoimmune hemolytic anemia, transfusion-related hemolysis, congenital hemolytic anemia (e.g., sickle cell disease), mechanical hemolysis (e.g., burns, prosthetic heart valve dysfunction)
- Malignant disease
 - Lymphoma, leukemia, solid tumours, tumour lysis syndrome
- Infections
 - Pneumocystis pneumonia, tuberculosis, bacterial sepsis, bacterial meningitis, encephalitis, myocarditis, HIV
- Multiorgan dysfunction (particularly of lungs, kidneys and liver), often secondary to shock
- Myopathy
 - Rhabdomyolysis, autoimmune myopathies such as polymyositis and dermatomyositis, trauma
- Intracranial hemorrhage
- Myocardial injury
 - Type I myocardial infarction, demand ischemia, drug-induced injury
- Severe vitamin B₁₂ deficiency

Table 2: Laboratory results before and after treatment with intramuscular injections of vitamin B₁₂ for severe vitamin B₁₂ deficiency presenting as pseudo-thrombotic microangiopathy

Investigation	Reference range	Day since admission						
		Day 1	Day 2	Day 3*	Day 4	Day 5	Day 7	Day 35
Hemoglobin, g/L	135–175	45	103†	71	71	75	79	120
MCV, fL	80–100	111	93.1	94.4	92.5	96.3	98.8	89
Platelets, × 10 ⁹ /L	150–400	68	26	19	16	13	54	184
Leukocytes, × 10 ⁹ /L	4–11	2.9	2	2	2.8	2	4	3.7
Unconjugated bilirubin, µmol/L	0–12	58	50.7	51	55			
Lactate dehydrogenase, U/L	110–230	> 4500	4424			> 2000‡	1308	155
D-dimer, ng/mL	< 500		40 052	22 036	38 392	2875	1396	304
INR	0.9–1.2	1.4	1.2	1.3	1.3	1.3	1.4	1.1
Vitamin B ₁₂ , pmol/L	138–652		< 117					404

Note: INR = international normalized ratio, MCV = mean corpuscular volume.

*First dose of intramuscular vitamin B₁₂ given on day 3 of hospital admission.

†After transfusion of 4 units packed red blood cells.

‡Laboratory reported > 2000 U/L and not the exact value.

deficiency in our patient was uncertain. Although tests for both anti-parietal cell and anti-intrinsic factor antibodies were negative, we could not rule out pernicious anemia because of the modest test sensitivity of these antibody assays (90% and 60%, respectively).⁵

Hematologic manifestations of vitamin B₁₂ deficiency include megaloblastic anemia with macrocytic red blood cells and hypersegmented neutrophils, as seen in our patient (Figure 1). More severe deficiency can cause pancytopenia. Elevated methylmalonic acid and homocysteine levels can confirm the diagnosis of vitamin B₁₂ deficiency in cases where the serum vitamin B₁₂ level is inconclusive or borderline low.^{3,4}

Treatment for vitamin B₁₂ deficiency, regardless of cause, is oral or intramuscular vitamin B₁₂ supplementation. The intramuscular route is preferred as initial treatment for patients with neuropathy or pancytopenia.³ Pancytopenia typically resolves within 2 months of starting vitamin supplementation, whereas neurologic deficits may take 3 months or longer to resolve and, in some cases, are irreversible.^{3,4}

In its most severe form, vitamin B₁₂ deficiency can mimic thrombotic microangiopathies such as TTP. Cardinal features overlap with other thrombotic microangiopathies, including anemia with abnormal hemolytic markers, schistocytes on peripheral blood film, elevated LDH and thrombocytopenia (Table 3). It is estimated that 1%–3% of patients with severe vitamin B₁₂ deficiency present with pseudo-TMA.^{1,6}

Differentiating pseudo-TMA from TTP is essential, because TTP is associated with 80%–90% mortality if left untreated and is associated with a 1.4-fold increased risk of death and 2.9-fold increased risk of major thrombotic events if treatment is delayed by more than 24 hours.^{2,7} Acquired TTP is defined by autoantibodies causing severe ADAMTS13 enzyme deficiency, which is normally responsible for cleaving large, circulating von Willebrand factor multimers. In the absence of ADAMTS13, these multimers accumulate, causing microvascular occlusion (leading to microthrombosis and end-organ injury), platelet consumption (leading to thrombocytopenia) and shearing of red blood cells in the microcirculation (resulting in schistocytes on the peripheral blood film). The PLASMIC score is a clinical screening tool for severe ADAMTS13 deficiency; a high score of 6–7 has a positive predictive value of 72%, whereas a low score of 0–4 virtually rules out a diagnosis of TTP.⁸ The patient described in this case had a PLASMIC score of 5, neither confirming nor excluding TTP.

A definitive diagnosis of TTP is made by the presence of microangiopathic hemolytic anemia, with an ADAMTS13 level less than 10%. Unfortunately, ADAMTS13 testing has a turnaround time of days to weeks, so immediate empiric treatment for TTP should be started if there is a high index of suspicion. Treatment for TTP consists of immunosuppression and plasma exchange, which removes the ADAMTS13 inhibitor and replaces deficient ADAMTS13 from pooled plasma. Platelet transfusion is generally avoided given a theoretical risk of worsening

Table 3: Bloodwork abnormalities in pseudo-thrombotic microangiopathy (TMA) from vitamin B₁₂ deficiency, compared with thrombotic thrombocytopenic purpura (TTP) and disseminated intravascular coagulation (DIC)

	Pseudo-TMA from vitamin B ₁₂ deficiency (± DIC)	TTP	DIC
Hemoglobin	↓↓	↓	↓
MCV	↑	-/↑	-
Platelets	↓	↓	↓
Leukocytes	↓	-	-
Reticulocytes	-/↓	↑	↑
Peripheral blood film	Hypersegmented neutrophils, schistocytes (few), dacrocytes	Schistocytes	Schistocytes (few)
INR	-/↑	-	↑
aPTT	-/↑	-	↑
Fibrinogen	-/↓	-	↓
Creatinine	-	-/↑	-/↑
Unconjugated bilirubin	↑	↑↑	↑
Direct antiglobulin test	Negative	Negative	Negative
Lactate dehydrogenase	↑↑	↑	-/↑
Haptoglobin	↓	↓	↓
D-dimer, ng/mL	-/↑	-	↑↑
ADAMTS13, %	> 10	< 10	> 10
Vitamin B ₁₂ level	↓↓	-	-

Note: aPTT = activated partial thromboplastin time, ADAMTS13 = a disintegrin and metalloproteinase with thrombospondin motifs 13, INR = international normalized ratio, MCV = mean corpuscular volume.

thrombosis. Transfusion with red blood cells is not contraindicated. In contrast, treatment for pseudo-TMA from vitamin B₁₂ deficiency consists of vitamin supplementation alone.²

Misdiagnosis of severe vitamin B₁₂ deficiency is common in patients with pseudo-TMA. In a 2017 literature review, 39% of pseudo-TMA cases from vitamin B₁₂ deficiency were treated as TTP with plasma infusion or plasma exchange.⁹ A correct diagnosis was reached after a median of 2 weeks.⁹ Koshy and colleagues⁶ compared clinical features of patients with TTP and those with pseudo-TMA secondary to vitamin B₁₂ deficiency between 1997–2019. Compared with patients with TTP, those with pseudo-TMA had more severe anemia (mean hemoglobin 61 v. 94 g/L), higher mean MCV (109 v. 86 fL), higher mean LDH (3539 v. 1183 IU/L), lower mean reticulocyte fraction (0.4% v. 2.4%), lower mean absolute neutrophil count (2.4 v. 7.7 × 10⁹/L) and lower mean total bilirubin (1.6 v. 5.2 mg/dL). In addition, patients with pseudo-TMA typically had normal renal function and intrinsic factor antibodies (69% of patients). The PLASMIC score did not reliably differentiate between these disorders; patients with pseudo-TMA had a median score of 4.9 (intermediate probability of TTP), compared with 6.1 (high probability of TTP) among patients with TTP.

Overt DIC from severe vitamin B₁₂ deficiency, as seen in this patient, is uncommon.¹⁰ Disseminated intravascular coagulation is a clinical syndrome caused by widespread and inappropriate activation of coagulation, consumption of coagulation factors, fibrinolysis and production of fibrin degradation products. Typical causes include overwhelming infection, malignant disease, placental abruption and major trauma. Laboratory abnormalities in DIC include elevated D-dimer, severe thrombocytopenia, elevated international normalized ratio and hypofibrinogenemia. Similar to our patient, Aboona and colleagues¹⁰ showed that laboratory abnormalities of DIC from vitamin B₁₂ deficiency

resolved with vitamin B₁₂ supplementation alone. One proposed mechanism of DIC from vitamin B₁₂ deficiency is apoptosis of immature erythroblasts leading to release of neutrophil extracellular traps, causing microthrombi formation and consumption of coagulation factors.¹⁰

Conclusion

We describe a patient who had severe vitamin B₁₂ deficiency causing pancytopenia, pseudo-TMA and DIC. A vitamin B₁₂ level should be routinely ordered in patients with suspected TMA.

References

1. Bendapudi PK, Hurwitz S, Fry A, et al. Derivation and external validation of the PLASMIC score for rapid assessment of adults with thrombotic microangiopathies: a cohort study. *Lancet Haematol* 2017;4:e157-64.
2. Hassouneh R, Shen S, Lee O, et al. Severe vitamin B12 deficiency mimicking microangiopathic hemolytic anemia. *J Hematol* 2021;10:202-5.
3. Langan RC, Goodbred AJ. Vitamin B12 deficiency: recognition and management. *Am Fam Physician* 2017;96:384-9.
4. Langan RC, Zawistoski KJ. Update on vitamin B12 deficiency. *Am Fam Physician* 2011;83:1425-30.
5. Bizzaro N, Antico A. Diagnosis and classification of pernicious anemia. *Autoimmun Rev* 2014;13:565-8.
6. Koshy AG, Freed JA. Clinical features of vitamin B12 deficiency mimicking thrombotic microangiopathy. *Br J Haematol* 2020;191:938-41.
7. Sawler D, Parker A, Britto J, et al. Time from suspected thrombotic thrombocytopenic purpura to initiation of plasma exchange and impact on survival: a 10-year provincial retrospective cohort study. *Thromb Res* 2020;193:53-9.
8. Li A, Khalighi PR, Wu Q, et al. External validation of the PLASMIC score: a clinical prediction tool for thrombotic thrombocytopenic purpura diagnosis and treatment. *J Thromb Haemost* 2018;16:164-9.
9. Tun AM, Myint ZW, Hernandez CR, et al. Vitamin B12 deficiency-related pseudo-thrombotic microangiopathy might be misdiagnosed and treated with plasma product therapy: review of the literature and analysis of the reported cases. *Blood* 2017;130(Suppl 1):5576.
10. Aboona MB, Rapaich L, Etman A, et al. A rare presentation of pernicious anemia manifesting as disseminated intravascular coagulation. *J Med Cases* 2022;13:557-60.

Competing interests: None declared.

This article has been peer reviewed.

The authors have obtained patient consent.

Affiliations: Department of Medicine (McKee), Western University, London, Ont.; Department of Medicine (Salter, Mithoowani), McMaster University, Hamilton, Ont.

Contributors: All of the authors contributed to the conception and design of the work, drafted the manuscript, revised it critically for

important intellectual content, gave final approval of the version to be published and agreed to be accountable for all aspects of the work.

Content licence: This is an Open Access article distributed in accordance with the terms of the Creative Commons Attribution (CC BY-NC-ND 4.0) licence, which permits use, distribution and reproduction in any medium, provided that the original publication is properly cited, the use is noncommercial (i.e., research or educational use), and no modifications or adaptations are made. See: <https://creativecommons.org/licenses/by-nc-nd/4.0/>

Correspondence to: Siraj Mithoowani, siraj.mithoowani@medportal.ca

The section Cases presents brief case reports that convey clear, practical lessons. Preference is given to common presentations of important rare conditions, and important unusual presentations of common problems. Articles start with a case presentation (500 words maximum), and a discussion of the underlying condition follows (1000 words maximum). Visual elements (e.g., tables of the differential diagnosis, clinical features or diagnostic approach) are encouraged. Consent from patients for publication of their story is a necessity. See information for authors at www.cmaj.ca.