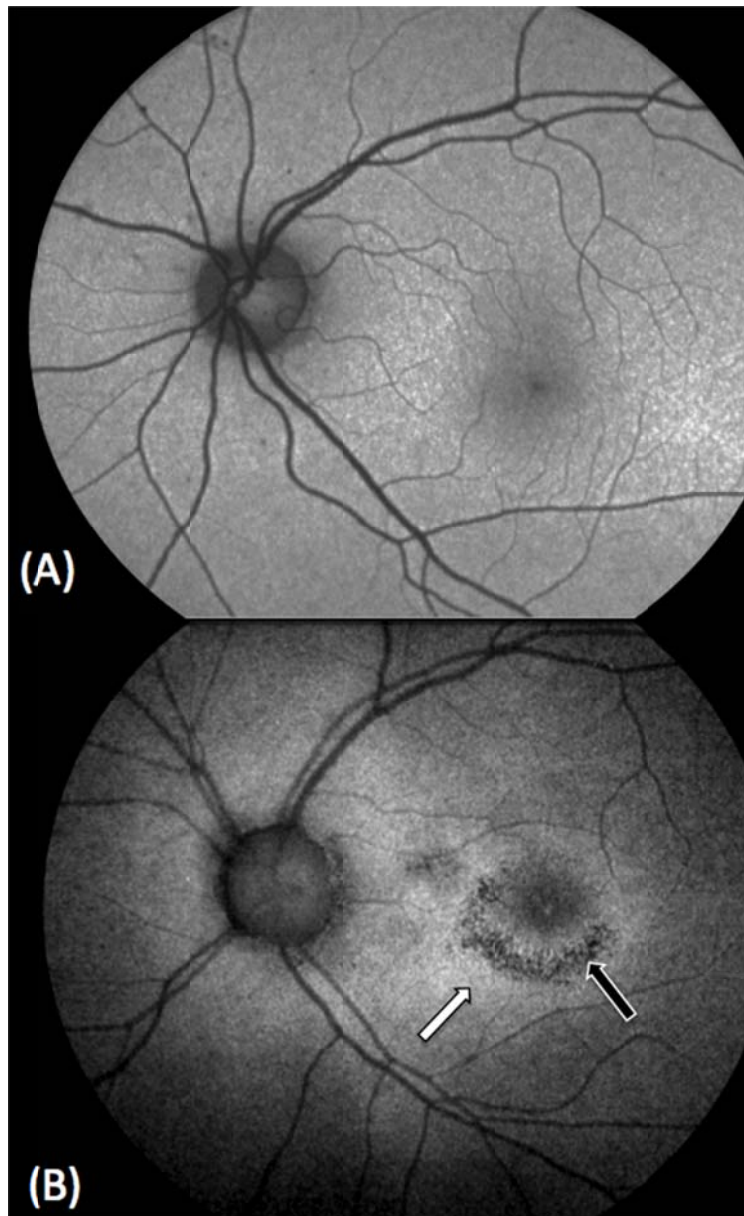


Appendix 1: Fundus autofluorescence images



Fundus autofluorescence images showing (A) normal findings from a control subject for comparative purposes and (B) bull's-eye maculopathy in the patient's left eye, with areas of hypoautofluorescence (black arrow) surrounded by areas of stippled hyperautofluorescence (white arrow) in the perifoveal region, which corresponds to regions of damage to the retinal pigment epithelium. These areas of damage seen on fundus autofluorescence correlate with the areas of decreased vision on visual field testing.