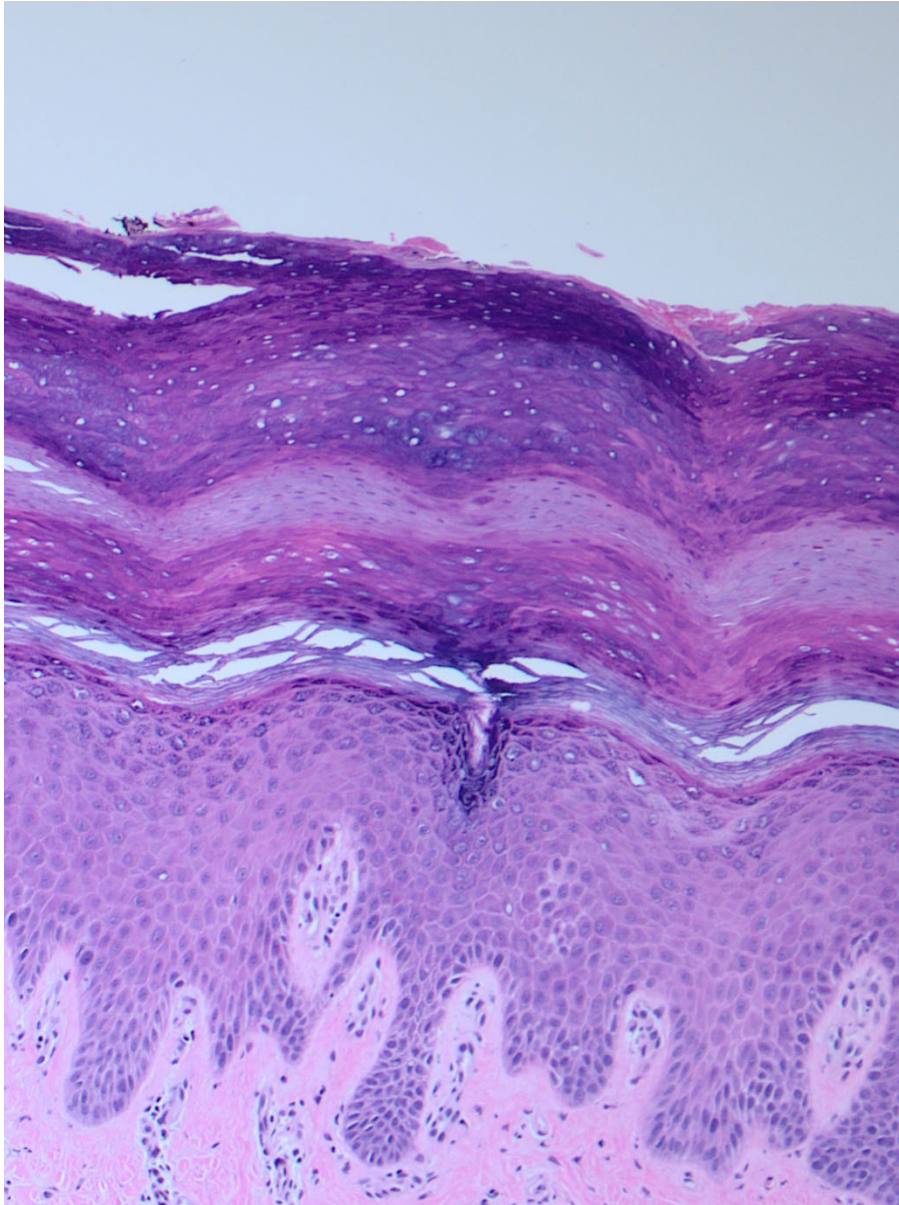


**Appendix 1 (as submitted by the authors): Supplementary figure**



Biopsy specimen showing alternating, vertical ortho- and para-keratosis compatible with the clinical impression of pityriasis rubra pilaris.