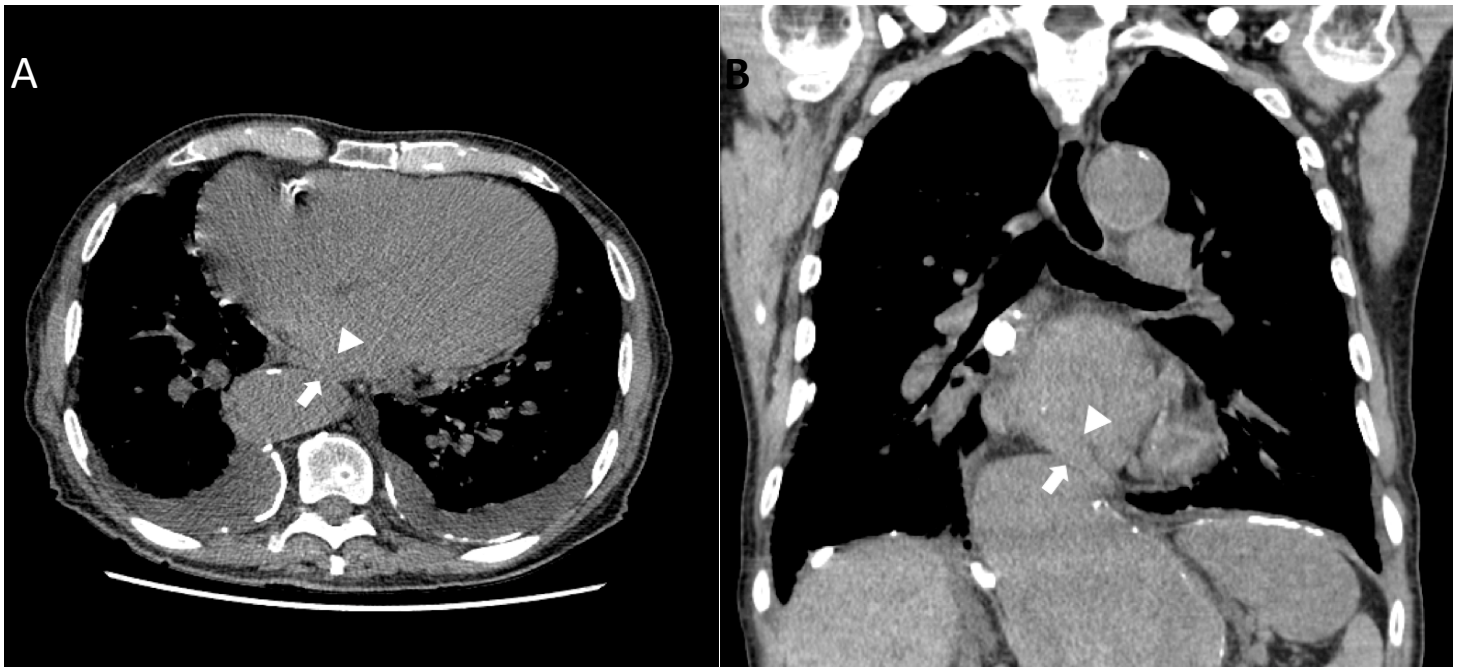


Appendix 1 (as submitted by authors): Supplementary figure



Axial (A) and coronal (B) CT images showing the esophagus being compressed between the aorta (white arrow) and the left atrium (arrowhead).