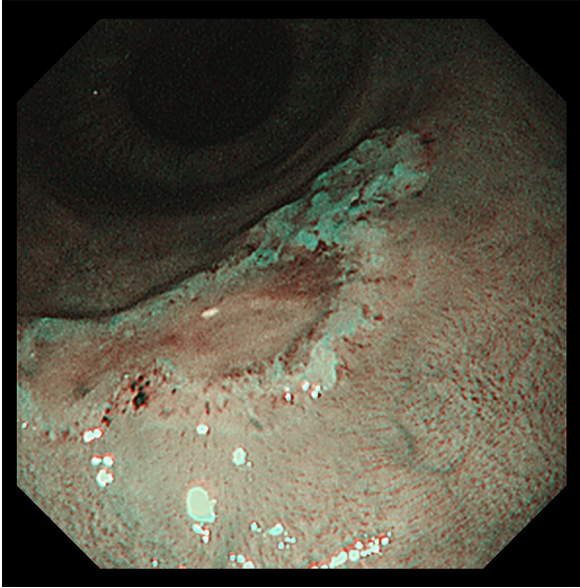


Appendix 1



Caption.

Appendix 1. Narrow-band imaging endoscopy showing volcano-like ulcers, a characteristic finding of herpetic esophagitis, in the distal esophagus.