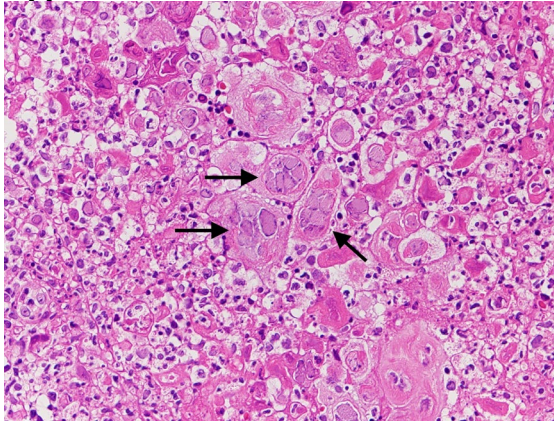


Appendix 2



Caption.

Appendix 2. Histopathological findings of a glossal biopsy by light microscope (high-power field) showing multinucleated cells with molded ground-glass nuclei (arrows).